



PRESENTING CLINICAL SIGNS

History: Murmur. Receiving Cardalis, clindamycin, and Novox.

DATE

7/19/22

ECHOCARDIOGRAPHIC FINDINGS

2D, M-mode, and Doppler study.

PERFORMED BY:

Kelly Vazquez

INTERPRETED BY

Keith Blass, DVM,
MS, DACVIM
(Cardiology)

There is mild left atrial dilation. The mitral valve leaflets are mildly thickened, a mild to moderate jet of eccentric mitral regurgitation is present. There is mild left ventricular dilation. Left ventricular systolic function is hyperdynamic. The aorta and aortic valve are normal. Right atrial and right ventricular dimensions are normal. The tricuspid valve leaflets are mildly thickened, and a mild jet of tricuspid regurgitation is present. TR velocity does not suggest the presence of pulmonary hypertension. The pulmonary artery and pulmonic valve appear normal, though trace pulmonic insufficiency is present. No shunting lesions are visualized. No pericardial effusion or cardiac masses are seen.

LA - 31.0 mm
LVIDd - 30.5 mm
LVIDs - 14.8 mm
FS - 51.5%
RA - 21.6 mm
LVOT - 1.13 m/s
RVOT - 0.50 m/s
TR - 2.41 m/s

PATIENT

Shane Camilleri

SPECIES

Canine

ASSESSMENT/RECOMMENDATIONS

Degenerative mitral and tricuspid valve disease

BREED

Shih Tzu Mix

This examination demonstrates regurgitation of blood across Shane's mitral and tricuspid valves resulting from degenerative valve disease. Shane's tricuspid valve disease is mild, and appears to be well-compensated at this time. His mitral valve disease is a bit more advanced, as Shane has mild to moderate mitral regurgitation present, with mild secondary dilation of both his left atrium and left ventricle, though his left ventricular systolic function is well-preserved. As only mild left heart chamber dilation is present, it's unlikely that Shane's cough is cardiogenic in origin, and his current risk for the development of other clinical signs secondary of cardiac dysfunction, such as exercise intolerance, syncope, and labored breathing, appears to be relatively low.

SEX

MN

Thoracic radiographs are recommended to further evaluate Shane's cough.

AGE

11 y

I recommend starting Shane on pimobendan (2.5 mg BID), as this medication should help to slow the progression of his valvular diseases. Shane's current therapy with Cardalis may be continued, if desired, though there is no definitive evidence proving a benefit of the medication at this stage of disease.

WEIGHT

18.8 lb

A recheck echocardiogram is recommended in 9 months.

HOSPITAL NAME

Willowbrook AC

REFERRING VET

Dr. Palesscandolo



DATE

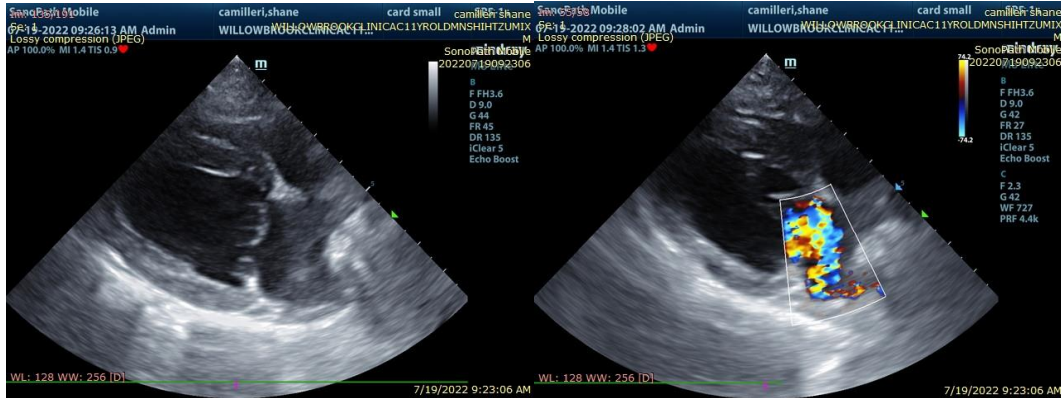
7/19/22

PERFORMED BY:

Kelly Vazquez

INTERPRETED BY

Keith Blass, DVM,
MS, DACVIM
(Cardiology)



The information and recommendations provided are based on the images presented by the referring veterinarian. No evaluation can be communicated regarding pathology that was not visible in the image/video clips provided.

PATIENT

Shane Camilleri

Thank you for this referral. If the clinical or image interpretation does not parallel your findings or if I can be of any further assistance please contact me.

SPECIES

Canine

Keith Blass, DVM, MS, DACVIM (Cardiology)
KeithBlass@gmail.com
631-804-5754

BREED

Shih Tzu Mix

SEX

MN

AGE

11 y

WEIGHT

18.8 lb

HOSPITAL NAME

Willowbrook AC

REFERRING VET

Dr. Palesscandolo